



International Journal of Research in Pharmacology & Pharmacotherapeutics (IJRPP)

IJRPP | Volume 12 | Issue 3 | July - Sept – 2023
www.ijrpp.com

ISSN:2278-2648

Case Study

Medical research

Oral intake of a widely available gastrointestinal OTC medicine 'Seirogan' is effective for gastric anisakiasis (*Anisakis* food poisoning)

Takuya Matsuoka¹, Tatsuomi Matsuoka^{2*}

¹Kyoshin Co. Ltd., Takarazuka 665-0044, Japan

²Emeritus professor, Department of Biological Science, Faculty of Science and Technology, Kochi University, Kochi 780-8520, Japan.

Corresponding author: Tatsuomi Matsuoka

Published on: 08.08.2023

ABSTRACT

Gastric food poisoning due to anisakid nematodes (gastric anisakiasis) is characterized by severe stomach pain caused by the consumption of raw fish that harbors anisakid nematodes. The only effective treatment that is currently available is the endoscopic removal of nematodes penetrating the stomach wall. An *in vitro* study showed that the widely available over-the-counter (OTC) gastrointestinal medicine 'Seirogan' containing wood creosote kills *Anisakis* larvae. In addition, two cases in which the oral intake of Seirogan alleviated gastric anisakiasis symptoms have been reported. Herein, we analyzed 56 statements regarding Seirogan's efficacy against gastric anisakiasis posted on social networking sites (SNSs) in Japan. There were 33 statements (59%) that Seirogan was effective in significantly alleviating or eliminating symptoms of gastric anisakiasis, 13 comments (23%) stating that it had a slight effect, and 10 comments (18%) stating that there was no effect. These results indicate that in many cases, an oral intake of Seirogan is effective as first aid to remove or alleviate severe stomach pain due to gastric anisakiasis.

Keywords: *Anisakis*, gastric anisakiasis, Seirogan, wood creosote.

INTRODUCTION

Gastric food poisoning due to anisakid nematodes (gastric anisakiasis) is characterized by unbearable stomach pain due to a penetration of anisakid nematodes into the stomach wall. Gastric anisakiasis is caused by eating raw fish such as 'sashimi' that harbors nematodes such as *Anisakis simplex* (see Fig. 1), *A. pegreffii* and *Pseudoterranova decipiens* [1,2]. The only effective treatment that is currently available for gastric anisakiasis is the endoscopic removal of nematodes that have penetrated the stomach wall [3]. Severe stomach pain due to gastric anisakiasis occurs within several hours to 12 hr after eating raw fish harboring anisakid nematodes. The symptoms usually appear in the middle of the night, since raw fish is usually eaten for dinner. Emergency department

physicians who can perform the necessary endoscopy for gastric anisakiasis symptoms are often not available in the middle of the night. Therefore, the development of an oral therapeutic medicine for gastric anisakiasis is desired.

Ten years ago, an *in vitro* experiment showed that a widely available over-the-counter (OTC) medicine called 'Seirogan' containing wood creosote [4], which is a traditional gastrointestinal medicine that has been used for >100 years in Japan, quickly suppressed the motility of *Anisakis* larvae [5]. More recent *in vitro* experiments demonstrated that the Seirogan components killed the majority of *Anisakis* larvae at the concentration of three pills (i.e., the single dose)/30 ml of 0.01 M HCl (corresponding to a volume of fasting gastric juice and HCl concentration contained in it), and the killed nematodes were digested in the solution that mimicked

gastric juice (0.01 M HCl containing pepsin) [6]. These *in vitro* results suggested that *Anisakis* larvae attached to the stomach wall may be killed by this single dose if three pills of Seirogan are completely dissolved in 30 ml of gastric fluid in the fasted state.

Actually, two cases in which an oral intake of Seirogan alleviated patients' gastric anisakiasis symptoms have been reported [5]. In the present study, we examined the efficacy of the oral intake of Seirogan for gastric anisakiasis (including self-diagnosis) based on statements posted on social networking sites (SNSs) in Japan.

METHODS

We analyzed 56 statements (all we could find except for a few poorly written posts) on the "efficacy of oral intake of Seirogan on gastric anisakiasis (including self-diagnosis)"

posted on SNSs in Japan between April 4, 2015 and June 13, 2023. Many of the posts were personal comments on yahoo news and other scientific news regarding gastric anisakiasis.

RESULTS AND DISCUSSION

Figure 2 depicts the efficacy of the oral intake of Seirogan on gastric anisakiasis based on the statements posted on the SNSs. Thirty-three (59%) of the posters on the SNSs stated that Seirogan was effective in significantly alleviating or eliminating severe stomach pain, while 13 (23%) stated that it was slightly effective, and 10 (18%) stated that it was not effective at all. In many cases, the posters self-diagnosed gastric anisakiasis because severe gastric pain appeared within about 12 hr after they had consumed raw fish.




Fig 1: Living larvae of *Anisakis simplex*.

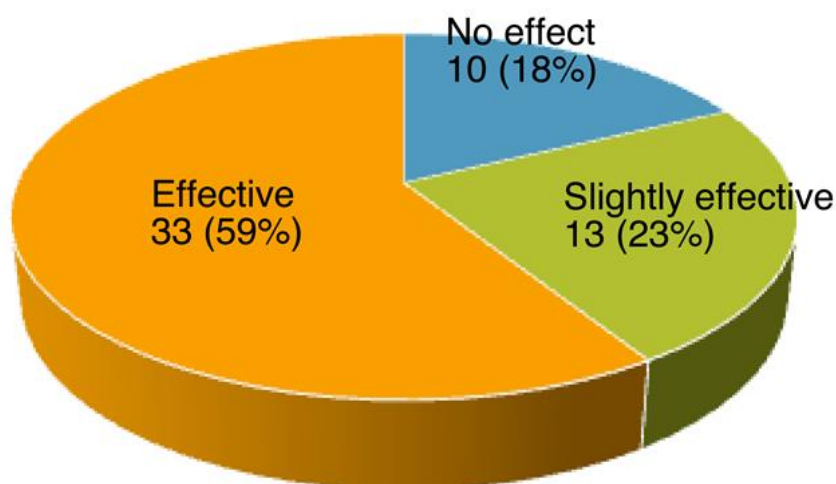


Fig 2: Effects of the oral intake of Seirogan on gastric anisakiasis.

Case reports

The following are representative cases for each category of Seirogan's effectiveness for gastric anisakiasis symptoms (effective, slightly effective, no effect) in the pie chart shown in Fig 2. These case reports are excerpts and/or summaries of personal comments on yahoo news (already deleted) and other scientific news regarding gastric anisakiasis (URLs listed below).

<https://news.yahoo.co.jp/articles/047619a53f052cf726dd3dd4314a29304c79faa0>;

<https://news.yahoo.co.jp/articles/4be8b19b757d56e9d4d4cae73183eab3004dae1>;

<https://news.yahoo.co.jp/articles/bfaf2b5d87a2c8c09c9057b4881ac719179b6ec1>;

<https://nazology.net/archives/95980/2>;

<https://moyarin.com/12547.html>

Seirogan was effective

Cases in which the posters' symptoms relieved significantly or disappeared completely after oral intake of Seirogan.

Case 1

After eating raw fish (sashimi), this poster had periodic severe stomach pain in the middle of the night. However, (s)he hesitated to call an ambulance because it was in the middle of the night. (S)he got information on a SNS that Seirogan was effective for gastric anisakiasis, and reported that after taking the Seirogan, the pain went away within a few minutes.

Case 2

After eating raw fish (bonito sashimi), this poster suffered from severe stomach pain in the middle of the night. After taking Seirogan, (s)he had almost no pain until they went to the hospital the next day. The examination at the hospital identified an anisakid nematode that had stopped moving, and it was easily removed.

Case 3

After eating raw fish (sashimi), this poster had such severe abdominal pain that he could not stand up and walk. After he took Seirogan, the pain subsided within an hour or so and he became able to walk. When he was examined at a hospital, the anisakid nematode had already been expelled.

Seirogan was slightly effective

Cases in which the posters' symptoms relieved somewhat after the oral intake of Seirogan.

Case 1

Seirogan was effective in delaying the cycle of pain and relieving it to some extent. This poster was able to tolerate the pain by taking Seirogan for one day, but on the second day, (s)he went to the hospital and had a nematode removed with endoscope.

Case 2

Seirogan reduced the poster's stomachache to about one-

third, but the poster's stomach hurt for 3 days.

Seirogan had no effect

Cases in which the posters' symptoms was not relieved at all after the oral intake of Seirogan.

Case 1

This poster was attacked by an anisakid nematode hidden in raw squid. He took Seirogan but it did not work to relieve symptom of anisakiasis. He then had the nematode removed via endoscopy at a hospital.

Case 2

This poster had such terrible abdominal pain that (s)he could not move and her (his) saliva overflowed. (S)he took Seirogan and other stomach medicine but they were not effective in relieving symptom of anisakiasis. (S)he suffered from pain for more than 4 days.

In many of the SNS posters' statements, the dosage of Seirogan taken was not described accurately. Some people took more than the maximum dosage. Many of the posters who reported no effect of Seirogan and those who experienced a slight effect received a diagnosis of gastric anisakiasis at a hospital. On the other hand, most of the posters whose symptoms improved dramatically after taking Seirogan did not seek medical attention, and thus there is no medical evidence that these posters had gastric anisakiasis; rather, they were self-diagnosed because they had a severe stomachache after they ate raw fish.

Our survey identified a 41% rate of cases in which Seirogan was not sufficiently effective. The following are possible causes of inadequate efficacy of Seirogan.

(1) The Seirogan concentration in the stomach may not reach the lethal concentration to kill almost all anisakid nematodes. *In vitro* experiments [6] showed that 13.3% of nematodes treated with Seirogan solution (1 pill/10 ml) were still moving 24 hr later, and 8.3% of nematodes whose motility had completely ceased at 24 hr were still alive (not stained with trypan blue). Thus, about 20% of Seirogan-treated nematodes remained alive. In addition, the Seirogan concentration in the stomach will not reach lethal concentrations if the Seirogan pills are not crushed completely, or when the Seirogan is taken with a large amount of water.

(2) Anisakid nematode penetrates the stomach wall so deeply that only the the posterior portion of the nematode body is exposed to the Seirogan solution. In this case, it is difficult to kill the anterior portion penetrating the stomach wall. The *in vitro* experiment showed that the posterior portion of nematodes that were dipped in Seirogan solution stopped moving soon but the remaining anterior portion continued to actively move [6], supporting this speculation.

(3) Anisakid nematodes penetrate the upper part of the stomach, making it difficult for it to be exposed to Seirogan solution.

It is possible that anisakid nematodes that are weakened and detached from stomach wall by exposure to Seirogan solution migrate to the intestine and reactivated nematodes may penetrate the intestinal wall. In this case, the nematodes can not be removed with the use of an endoscope. In the present survey, there was no such report. Further clinical studies

should be conducted to determine whether such risks may arise, and to establish the safe and effective dosage and usage of Seirogan to kill the majority of or all anisakid nematodes present in the stomach.

CONCLUSION

The results of the present survey revealed that in many cases, an oral intake of Seirogan was effective as first aid to remove or alleviate severe stomach pain due to gastric anisakiasis.

REFERENCES

1. Sakanari JA, McKerrow JH. Anisakiasis. *Clin Microbiol Rev.* 1989;2(3):278-84. doi: 10.1128/CMR.2.3.278, PMID 2670191.
2. Aibinu IE, Smooker PM, Lopata AL. *Anisakis* nematodes in fish and shellfish- from infection to allergies. *Int J Parasitol Parasites Wildl.* 2019;9:384-93. doi: 10.1016/j.ijppaw.2019.04.007, PMID 31338296.
3. Pravettoni V, Primavesi L, Piantanida M. *Anisakis simplex*: current knowledge. *Eur Ann Allergy Clin Immunol.* 2012;44(4):150-6. PMID 23092000.
4. Ogata N, Tagishi H, Tsuji M. Inhibition of acetylcholinesterase by wood creosote and simple phenolic compounds. *Chem Pharm Bull (Tokyo).* 2020;68(12):1193-200. doi: 10.1248/cpb.c20-00583, PMID 33268651.
5. Sekimoto M, Nagano H, Fujiwara Y, Watanabe T, Katsu K, Doki Y, et al. Two cases of gastric anisakiasis for which oral administration of a medicine containing wood creosote (Seirogan) was effective. *Hepato-Gastroenterology.* 2011;58(109):1252-4. doi: 10.5754/hge11052. PMID 21937389.
6. Matsuoka K, Matsuoka T. Over-the-counter medicine (Seirogan) containing wood creosote kills *Anisakis* larvae. *Open J Pharmacol Pharmacother.* 2021;6(1):9-12. doi: 10.17352/ojpp.000017.