



## International Journal of Research in Pharmacology & Pharmacotherapeutics



ISSN Print: 2278-2648  
ISSN Online: 2278-2656

IJRPP | Vol.5 | Issue 1 | Jan- Mar - 2016  
Journal Home page: [www.ijrpp.com](http://www.ijrpp.com)

Research article

Open Access

### A study on colposcopic directed biopsy in early detection of premalignant and malignant lesions of cervix

<sup>1\*</sup>Dr.S.Vijaya laxmi, <sup>1</sup>Dr.Kishan Bookya.

<sup>1\*</sup>Assistant Professor, Department of Pathology, SVMC Medical College, Tirupati, Andhrapradesh, India.

<sup>1</sup>Associate Professor, Department of Pathology, ACSR Govt Medical College, Nellore, Andhra pradesh, India.

\*Corresponding author: Dr.S.Vijaya laxmi

#### ABSTRACT

The aim of the study is to determine the outcome of women referred for Colposcopy and directed biopsy with abnormal pap smears and smears showing persistent inflammation. Cervical cancer is a significant health problem worldwide among women. Cancer cervix is the most common cancer in developing countries. It is considered as preventable cancer since there is availability of screening method and effective diagnostic and therapeutic procedures. Despite the accuracy and efficacy of cervical cytology in detecting and diagnosing cervical neoplasia, it must remain a screening technique with further evaluation based on histologic diagnosis. The objectives of the study are To study the Colposcopic features of abnormal pap smears and persistent inflammatory cellular changes on pap smear, To localize the lesion by Colposcopy and obtain a biopsy, To assess the prevalence of CIN in the study group. To correlate pap smear findings with colposcopic findings, To study the epithelial cell abnormalities by colposcopic biopsy of abnormal areas in such cases, To determine the existence of significant cervical intraepithelial lesion or invasive carcinoma in patients with persistent inflammatory pap smear. The present study is undertaken to evaluate the role of cytology and Colposcopic guided biopsy in diagnosing neoplastic cervical lesions.

**Keywords:** Colposcopy, Cervical cancer, Cervical cytology, Histologic diagnosis, Pap smear.

#### INTRODUCTION

Carcinoma cervix is the commonest cancer responsible for about 5% of all cancer deaths in women worldwide. It's 5<sup>th</sup> deadliest cancer in women.<sup>1</sup> There are 1.7 million cases in the developing world and as many as 5-13 millions women have precancerous lesions<sup>2,3</sup>. It affects about 16 per 10000 women in a year and kills about 9 per 100000 per year.<sup>4</sup> Approximately 80% of cervical

cancers occur in developing countries<sup>5</sup> and it is the commonest cancer in these countries. The worldwide Pap smear has been the standard test for screening of cervical cancer and its precursors. However, it suffers from low sensitivity and has a high false negative rate of 9%-40%<sup>6,7,8</sup>, there is a possibility that an inflammatory pap smear may miss the cervical premalignant change. To overcome this problem many algorithms have been devised to manage

ASCUS or LSIL on Pap smear. These involve HPV DNA testing, colposcopy or both. However, no such algorithm is available for further management of an inflammatory pap smear. Chronic inflammation, either specific or nonspecific, has been shown to be associated with malignancy and was thought to be one of the factors responsible for carcinogenesis. Persistent inflammation leads to increased cellular turnover, especially in the epithelium, and provides a selection pressure that result in the emergence of cells that are at a high risk for malignant transformation<sup>9</sup>. Inflammatory pap smear is the most common report the gynecologist receives even where cervix appears normal. Since the incidence of inflammation on pap smear is very high (14%-19%)<sup>10,11,12</sup>, the cervical screening algorithm for benign cellular changes recommends treatment of infection if indicated and performing a repeat Pap smear in 4 to 6 months' time and, if the inflammatory changes persist, to subject the patient to colposcopy<sup>13</sup>. The realization that cervical intraepithelial neoplasia grade III is present in up to one third of women with mild or moderate dyskaryosis<sup>14, 15,16</sup> led to the suggestion that all women with any degree of dyskaryosis should be referred for Colposcopic assessment. The advantages of this approach are that it enables a prompt histological diagnosis and avoids the possibility of the patient defaulting on a further smear test. Recent guidelines on the management of women with such smears suggest immediate referral for Colposcopy for women with a single moderately dyskaryotic smear and referral after two consecutive dyskaryotic smears for women with mild dyskaryosis.<sup>17</sup> Colposcopy combined with Colposcopically directed biopsies are the primary modality by which women with abnormal pap smears are evaluated. Colposcopic examination consists of viewing the cervix with a long focal length, dissecting type microscope at a magnification of about 16x after a solution of dilute acetic acid has been applied to the cervix which causes acetiwhitening of abnormal areas. This coloration allows the Colposcopist to identify and biopsy epithelial lesions. Colposcopy and appropriately directed biopsy have greatly facilitated the management of the patients with pre invasive lesions of the cervix. It also allows the clinician to rule out the invasive cancer and determine the limits of the pre invasive disease. Conservative ablative modalities like cryosurgery, laser ablation, and loop

electrosurgical excision procedure can be used to treat pre invasive disease and obviate the need for a cone biopsy.

## MATERIALS AND METHODS

A prospective study was done for duration of 2Years from January 2010 to April 2012 on Colposcopic guided biopsy of cervical lesions in the department of pathology, Mahatma Gandhi Memorial Hospital and Government Maternity Hospital Warangal after obtaining clearance from the ethical committee.

### Exclusion criteria

Pregnant women, known cases of CIN and obvious cervical growth, IUCD users, Diabetes mellitus, Women with multiple sexual partners, Patients with previous cervical surgery.

### Inclusion criteria

Women between 20-65 and above, Women with symptoms like vaginal discharge, post coital bleeding, Inter menstrual /irregular bleeding, Persistent leucorrhoea not responding to treatment, Persistent inflammatory changes in pap smear, Women having abnormal pap smear (intraepithelial abnormalities), Patients with a report of abnormal pap smear and persistent inflammatory pap smear were included in the study.

Those with a clinical diagnosis of chronic pelvic inflammatory disease and showing inflammatory Pap smear were treated with antimicrobial and anti-inflammatory treatment, according to WHO guidelines.<sup>18</sup> These patients were given doxycycline and metronidazole orally for 7-14 days and Clotrimazole vaginal pessaries daily for a minimum of 6 days. A repeat Pap smear was performed after a period of 2 weeks. No preparation of the cervix was undertaken at the time sampling and women were not menstruating or using any vaginal douche or vaginal contraceptives at the time of sampling. If the inflammatory cellular changes were reported again on repeat pap smear, were said to have a persistent inflammatory smear. These patients along with abnormal pap smear report were subjected to colposcopy and directed biopsy after taking the informed consent.

Conventional cytology testing was obtained by scraping the cervical cells with a cotton swab and the smear was prepared by spreading the specimen

uniformly across a glass slide, which was immediately fixed in 95% ethyl alcohol contained in a Coplin jar. Then smear was stained with Papanicolaou stain and cytology results were reported, according to the Bethesda system.<sup>19</sup>

### Procedure for Colposcopic guided biopsy

The women were kept in a dorsal position and the cervix was exposed by inseting at Cusco's speculum. Excess mucous was wiped off with cotton swab soaked in saline. Five percent acetic acid was applied to the cervix and it was visualized with binocular Colposcope under 40X magnification. Biopsies were taken from the abnormal areas (acetowhite areas and vascular abnormalities like fine punctuation, coarse punctuations, mosaic and areas showing atypical vasculature). A biopsy specimen obtained were fixed in formalin and processed and subjected for

histopathological examination. The incidence of premalignant and malignant lesions was calculated as percentages.<sup>20</sup>

## RESULTS

In the study "Colposcopic guided biopsy of cervical lesions", evaluated 114 patients aged between 20-65 years and above age group from January 2010 to April 2012 in Mahatma Gandhi Memorial Hospital Warangal.

### Age distribution

Out of 114 patients 40 (35.08%) were between 41-50 years, least age group in our study were 65 yrs and above and all observations shown in both table and figure number 1.

Table 1 Age distribution.

Age	No. of cases	%
21-30	10	8.77%
31-40	37	32.45%
41-50	40	35.08%
51-60	19	16.66%
61-70	8	7.01%

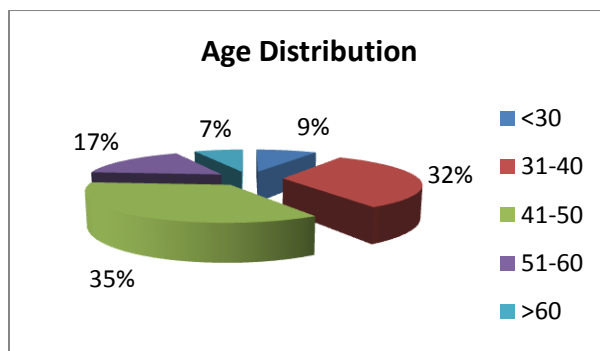


Figure 1 Age distribution

### Clinical Symptoms

Out of 114 patients, 57 patients presented with white discharge results as shown in both table and figure number 2.

Table 2 Clinical Symptoms

Clinical symptoms	No. of cases	%
White discharge	57	50%
Pelvic pain	21	18.42%
AUB	12	10.52%
Mass per vagina	5	4.38%
Post coital bleeding	8	7.01%
Post menopausal bleeding	5	4.38%
Dysmenorrhoea	6	5.26%

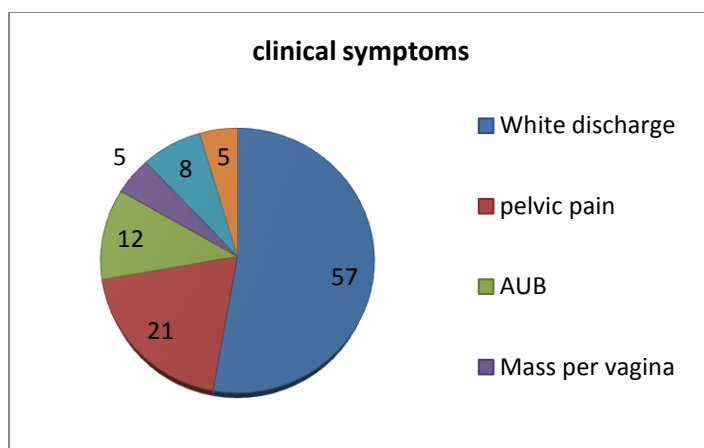


Figure 2 Clinical Symptoms

### Colposcopic Findings

Among 114 patients acetowhite areas were seen in 44 patients, 27 were having combined acetowhite and

vascular abnormalities' and observations were shown in both table and figure number 3.

Table 3 Colposcopic Findings

Clinical symptoms	Normal	Erosion	AW areas	Vascular abnormality	AW+Vascular abnormality	Total
Vaginal discharge	3	9	20	9	16	57
Pelvic pain	1	3	10	3	4	21
AUB	-	-	4	5	3	12
Post coital bleeding	-	4	3	-	1	8
Mass per vagina	-	-	2	1	2	5
Post menopausal bleeding	-	-	3	1	1	5
Dysmenorrhea	2	2	2	-	-	6
Total	6	18	44	19	27	114

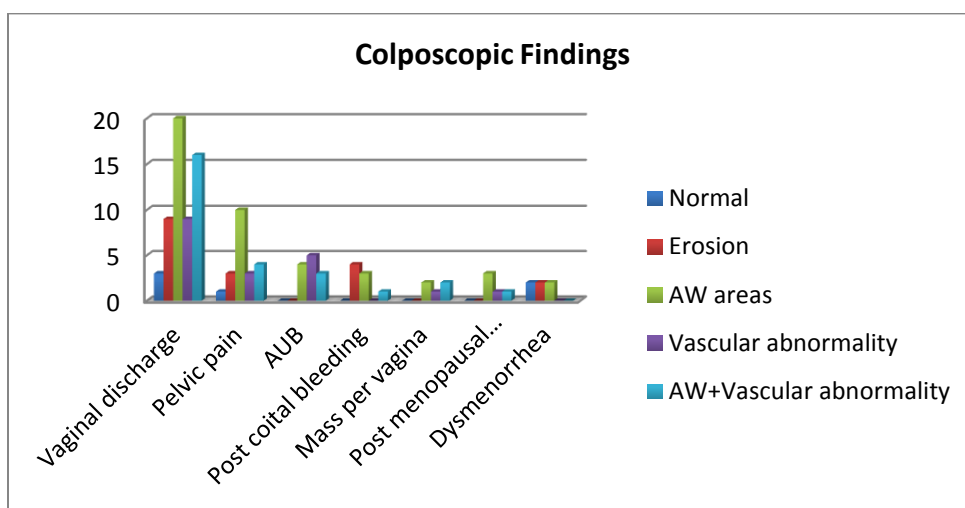


Figure 3 Colposcopic Findings

### Persistent Inflammation Correlated with Histopathology

In persistent inflammation group vaginal discharge was the commonest symptom (25patients)

in which 11 patients were diagnosed to have CIN I changes and results were shown in both table and figure number 4.

Table 4 Persistent Inflammation Correlated with Histopathology

Clinical symptom	Normal cervix	Chronic cervicitis	CINI/HPV	CIN II	CIN III	Invasive cancer	Total
Vaginal discharge	4	10	11	-	-	-	25
Pelvic pain	2	5	4	-	1	-	12
AUB	-	3	4	-	-	-	7
Pot coital bleeding	-	-	2	1	-	-	3
Mass per vagina	-	1	1	-	-	-	2
Post menopausal bleeding	-	-	-	1	-	-	1
Dysmenorrhea	3	2	1	-	-	-	6

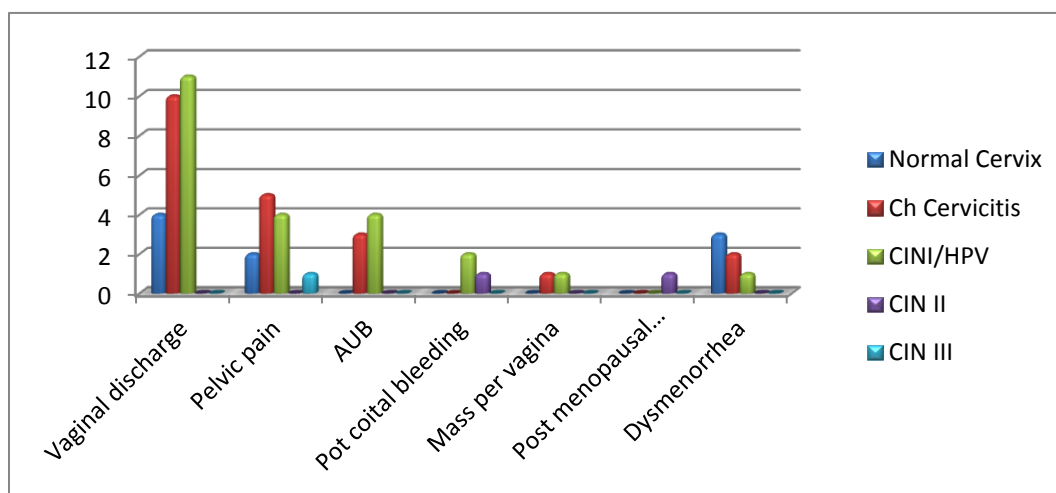


Figure 4 Persistent Inflammation Correlated with Histopathology

### Abnormal Pap smear findings

In the 2 Year study period have screened 760 women, out of which 52(7.2%) women were having an abnormal Pap smear, 62 (8.6%) were having persistent inflammation. Out of 52 abnormal Pap smears 28 showed(LSIL) low grade squamous

intraepithelial lesions,12 showed ASCUS, 8 were having HSIL and 4 patient were positive for invasive cancer and results shown in both table and figure number 5.

Table 5 Abnormal Pap smear findings.

Abnormal pap smear finding	No. of cases	Total %
LSIL	28	3.9%
HSIL	8	1.1%
ASCUS	12	1.6%
Invasive cancer	4	0.6%
Inflammatory smear,atrophic cervix,normal study	668,	92.77%

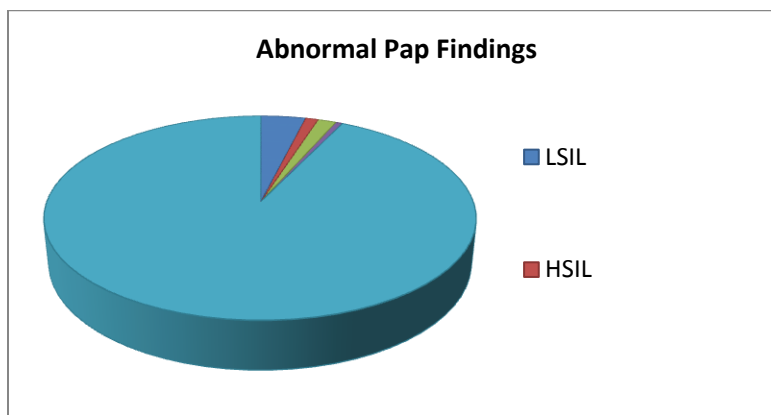


Figure 5 Abnormal Pap smear findings

### Abnormal Pap smear Correlated with Colpohistology

Out of 28 LSIL cases, 10 were having no evidence of premalignant or malignant condition. 13 patients (46.4%) found to have CIN I and 5 patients were having a high grade disease (17.89%) results as shown in both table and figure number 6.

Table 6 Abnormal Pap smear Correlated with Colpohistology

Biopsy finding	ASCUS	LSIL	HSIL	Invasive cancer	Total
Negative	5 (41.66%)	10(35.7%)	1(12.6%)	-	16
CIN I	3 (25%)	13 (46.4%)	1 (12.6%)	-	17
CIN II	2 (16.66%)	3 (10.75)	2 (25%)	1 (25%)	8
CIN III	1 (8.33%)	2 (7.14%)	3 (37.5%)	2 (50%)	8
Invasive cancer	1 (8.33%)	-	1 (12.6%)	1 (25%)	3

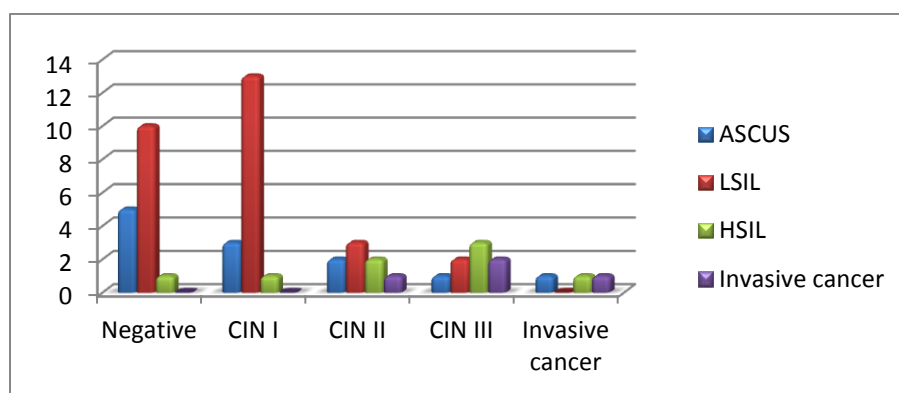


Figure 6 Abnormal Pap smear Correlated with Colpohistology

### Persistent Inflammation Correlated with Histology

62 patients had persistent inflammation on Pap smear among 720 routine Pap smears. 6 patients had normal Colposcopic findings and rest of 56 patients

who had persistent inflammation on Pap smear have undergone colposcopic directed biopsy. Out of 56 patients 23 were having CIN I changes and 1 case diagnosed as CIN III and no invasive cancer was found in this study group and observation was shown in both table and figure number 7.

Table 7 Persistent Inflammation Correlated with Histology

Biopsy finding	No. of cases	Total %
Normal cervix	9	16.07%
Chronic cervicitis	21	37.50%
CIN I/HPV changes	23	41.07%
CIN II	2	3.57%
CIN III	1	1.78%
Invasive cancer	-	-

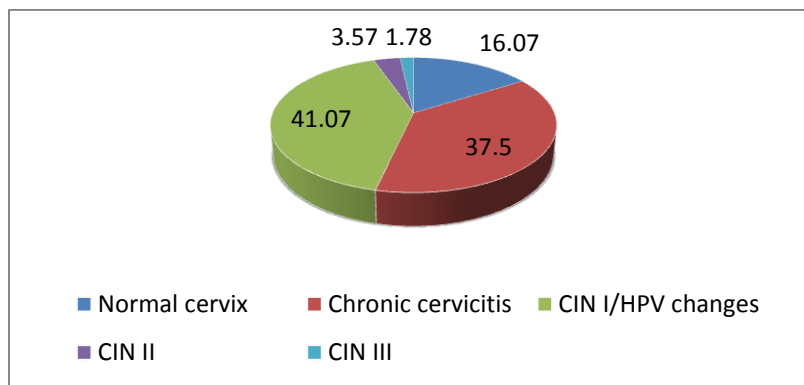


Figure 7 Persistent Inflammation Correlated with Histology

### Final Histopathology Reports of both Abnormal and Persistent Inflammatory Pap smears

In abnormal Pap smear group out of 52 patients, 17 were CIN I group and 3 patients were diagnosed to have invasive cancer. In persistent inflammation

group out of 62 patients 6 did not undergo biopsy since colposcopy was normal in these patients. So out of 56 patients 30 were having chronic cervicitis and 23 were diagnosed to have CIN I lesions and results were shown in both table and figure number 8.

Table 8 Final Histopathology Reports of both Abnormal and Persistent Inflammatory Pap smears

Biopsy report	Abnormal pap smear	Persistent inflammatory smear
Chronic cervicitis	16 (30.76%)	30 (53.57%)
CIN I	17 (32.69%)	23 (41.07%)
CIN II	8 (15.38%)	2 ( 3.57%)
CIN III	8 (15.38%)	1 ( 1.78%)
Invasive cancer	3 (5.76%)	0

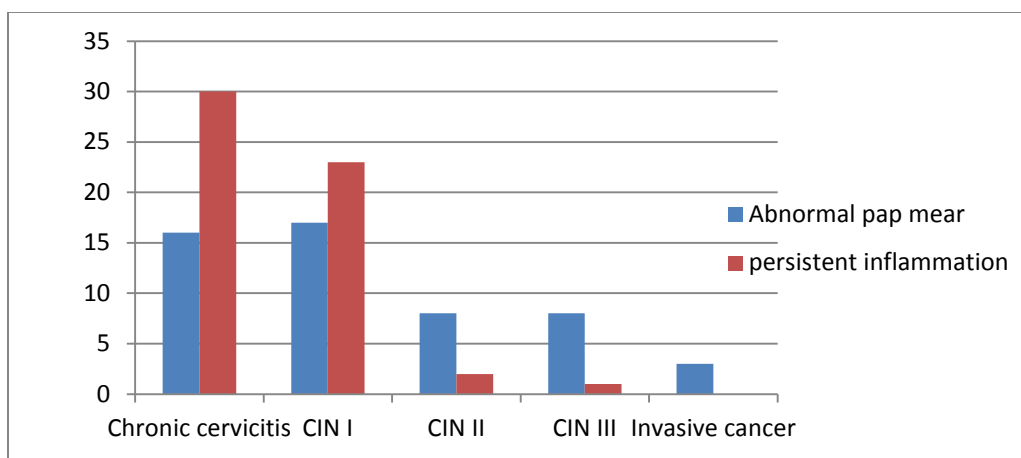


Figure 8 Final Histopathology Reports of both Abnormal and Persistent Inflammatory Pap smears

### Pap smear finding-age distribution

Among 114 patients Pap smears seen in 40 patients between age group 41-50 Years, 37 patients between age group 31-40 Years, 19 patients between

age group 51-60 Years, 10 patients between age group <30 Years, 8 patients between age group >60 Years results were shown in both table and figure number 9.

Table 9 Pap smear finding-age distribution

Age	Inflammatory smear	LSIL	HSIL	ASCUS	Invasive cancer	Total
<30 yr	8	2	-	-	-	10
31-40yr	22	8	1	5	1	37
41-50yr	18	10	6	4	2	40
51-60yr	9	6	1	3	-	19
>60 yr	5	2	-	-	1	8

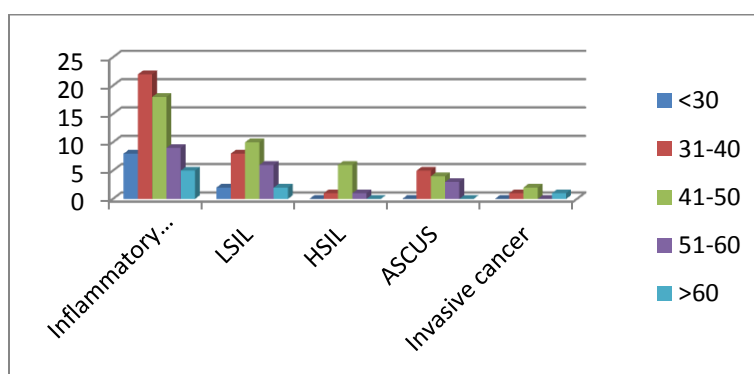


Figure 9 Pap smear finding-age distribution

### Histopathology findings-age distribution

Among 114 patients, Negative for malignancy, Invasive cancer, CIN I,II and III etc seen in 40 patients between age group 41-50 Years, 37 patients between age group 31-40 Years, 19 patients between

age group 51-60 Years, 10 patients between age group <30 Years, 8 patients between age group >60 Years results were shown in both table and figure number 10.



Table 10 Histopathology findings-age distribution

Age	Negative for malignancy	CIN I	CIN II	CIN III	Invasive cancer	Biopsy not done	Total
<30 yrs	6	3	-	-	-	1	10
31-40yr	16	11	2	4	-	4	37
41-50yr	12	17	6	2	2	1	40
51-60yr	9	8	1	1	-	-	19
>60yr	3	1	1	2	1	-	8

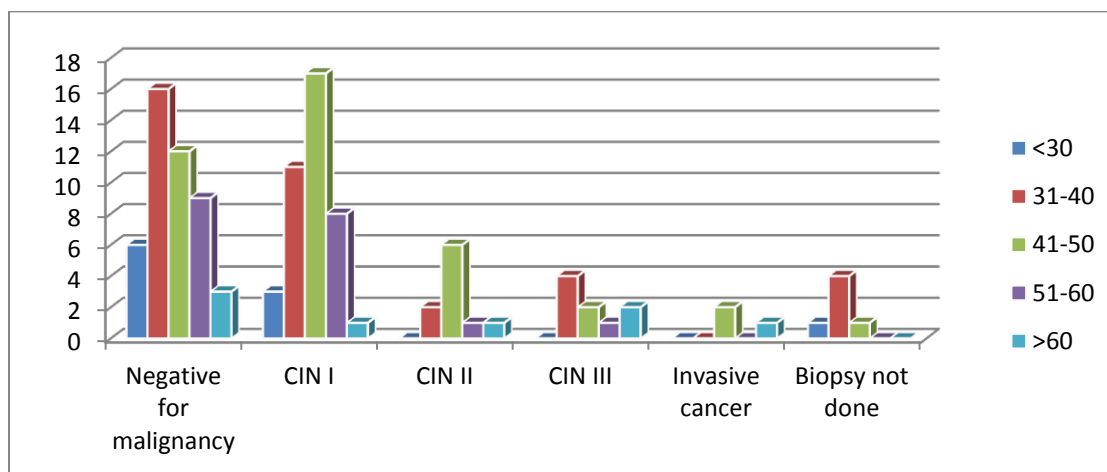


Figure 10 Histopathology findings-age distributions

## DISCUSSION

Cervical cancer screening was proved to be an important part of preventive health care of women. Attempts are being made to improve efficacy of the screening program to decrease the morbidity and mortality due to cervical cancer. Cytologic atypia reported on a routine Pap smear of the cervix frequently present a dilemma for the physician. Steps to evaluate of this entity depend on multiple factors, most important being whether the presence of underlying cervical neoplasia is suspect. Cervical cytological abnormalities are of concern because in a small but important number their reflex the presence of high grade CIN. The cervical cancer screening algorithm for benign cellular changes on Pap smear recommends treatment of infection and repeat Pap smear in 6-9 weeks if inflammatory changes persist to subject the patient to Colposcopy. In developing countries where proper screening protocols are not followed a good number of patients with premalignant stage are being missed. Most Gynecologists do not review the pap smear result with cytologist and 41% do nothing when the

inflammatory Pap smear is reported. Only 11% treat the infection and repeat Pap smear and 24% treat infection and do not repeat pap smear.<sup>21</sup> The detection rate of premalignant and malignant lesions of the cervix by guided biopsy of lesions in an abnormal pap smear group in the present study is as follows: In LSIL group CIN I constituted 46.4%, while CIN II, CIN III combined to have 17.84% In HSIL group CIN I constituted 12.6%, while CIN II and III combined to have 62.5%. Among 4 cases of invasive cancer CIN II, CIN III was reported in 75% cases and one case frank malignancy. In the study LSIL was diagnosed in 28 patients, further Colpocopic guided biopsy CIN I was diagnosed in 13 (46.4%) and CIN II & III constitutes 5 (17.84%) cases. And 10 (35.7%) cases were negative for malignancy and no invasive cancer was reported in LSIL group and LSIL group shows 17.84% women have high grade lesion who were under diagnosed by Pap smear were missed if not further investigations done and ASCUS was seen in 12 cases. Among, those 49.9% women had CIN lesions and high grade CIN lesions were 24.93%. A more common approach is to repeat the smear after a course of antibiotic or after an arbitrarily determined

time interval, then performs Colposcopy if atypical persist on repeat Pap smear. This “treat and repeat” or “wait and repeat” approach is possible in highly motivated people and aggressive protocol may be required if the sexual history and socioeconomic profile of the target population is a high risk category. A significant number of CIN cases were missed if atypia on Pap smear is not investigated further. HSIL was diagnosed in 8 patients, among them CIN II & III were diagnosed in 5 (62.5%) by biopsy and invasive cancer in 1 (12.6%). The detection rate of CIN II & III in the study is similar to chomet et al study and Boonlikit et al study which shows 67.8%. Women with HSIL can harbor high grade cervical lesion and prevalence of invasive carcinoma is also high. So immediate Colposcopy and Colposcopically directed biopsy is mandatory. Among 720 routine pap smears 4(0.6%) were positive for malignancy ,these cases are followed with Colposcopically guided biopsy and results shows 3 cases(75%) proved to be CIN II & III and 1 case(25%) invasive cancer,it shows smear positive for malignancy are inconsistent predictor of high grade premalignant lesions and invasive cancer. Persistent inflammation was seen in 62(8.2%) women among 760 routine pap smears. Histological diagnosis showed 21 (38.3%), 9(16.07) cases,chronic cervicitis and negative for any premalignant and malignancy respectively. Premalignant lesions 26(46.42%) were present in persistent inflammatory smear which were missed if not Colposcopic directed

biopsy was not done. Most cases were in CIN I group (41.07%) and 3 cases (5.35%) of CIN II & III. And no invasive cancer was seen in this group.

## CONCLUSION

A prospective study was done on “Colposcopic directed biopsy in early detection of premalignant and malignant lesion of cervix” in MGM Hospital Warangal for duration of 2 years. In the study group majority of premalignant and malignant lesions seen in 41-50 age group with a mean age of 42.6.Pap smears studied among 720 patients in the outpatient department, majority are negative for intraepithelial lesion or malignancy(92.77%)and abnormal Pap smears constitutes 7.2%(52cases.) Among these 52 cases LSIL, HSIL, ASCUS and Invasive cancer constitutes 3.9%, 1.1%, 1.6%, 0.6% respectively. Among 720 cases, 114 cases (52 cases of abnormal pap smears and 62 of persistent inflammation) were followed by Colposcopy and directed biopsy. Biopsy was not done 6 patients with persistent inflammation showing normal Colposcopic finding commonest finding in Colposcopy in the study was aceto white areas(44 Cases out of 114) 56 of these persistent inflammation group CINI, II, and III were seen in 41.07%,3.57%,and 1.78% respectively. Among 52 abnormal pap smear followed by Colposcopic guided biopsy CIN I in 32.69%, CIN II & III in 30.76% and invasive cancer in 5.7% of patients.

## REFERENCES

- [1]. World health organization (February 2006) fact sheet no 297; cancer, Retrieved 2007 – 12 - 01.
- [2]. Rejendra A Kalkar, Yogesh Kulkarni. Screening for cervical cancer: an overview. *Obstet Gynecol India* vol. 56 no. 2: March /April 2006.
- [3]. Mohammed Shaoaib Khan, Fohadiya Yasin Raja at el. Pap smear Screening for Precancerous conditions of the cervical cancers. *Pak J. Med. Res.*; vol. 44 no. 3, 2005:111-3.
- [4]. Globocan 2002 data base table by cancer, Retrieved 2008 -10 – 26.
- [5]. Kent A, HPV vaccination and testing, *Reviews in Obstetrics and gynaecology*, (2010), 3; 33 - 34.
- [6]. DiBonito L, Falconieri G, Tomaic G, Colautti I, Bonifacio D, Dudine S. Cervical Cytopathology: An evaluation of its accuracy based on Cytohistologic comparison. *Cancer* 1993; 72: 300-6.
- [7]. Wilkinson EJ, Paponicolou smear and screening for cervical neoplasia. *Obstet Gynecol* 1990; 35: 817-25.
- [8]. Gay JD, Donaldson LD, Goellner JR. False negative results in cervical cytological studies. *Acta Cytol* 1985, 29:1043-6.
- [9]. Moss F, Blaser MJ. Mechanism of Disease: Inflammation and origin of cancer/. *Nat Clin Pract Oncol* 2005; 2: 907.
- [10]. Seckin NC, Turhan NO, Ozmen S, Erssan F, Avoar F, Ustun H. Routine colposcopic evaluation of patients with persistent inflammatory cellular changes on pap smear. *Int Gynecol Obstet* 1997; 59: 25-9.

- [11]. McLachlan N, Patwardhan JR, Ayer B, Pacey NF. Management of suboptimal cytological smears. *Acta Cytol* 1994; 38: 531-6.
- [12]. Parashari A, Singh V, Gupta MM, Satyanarayana L, Chattopadhyaya D, Sodhani P, et al. Significance of inflammatory cervical smears. *APMIS* 1995; 103: 273-8.
- [13]. ACOG Practice Bulletin. Clinical management guidelines for Obstetrician and Gynecologist Cervical Cytology screening *Obstet Gynecol* 2003; 102:417-27.
- [14]. Walker EM, Dodgson J, Duncan ID. Does mild atypia on a cervical smear warrant further investigation? *Lancet* 1986; 2: 772-3.
- [15]. Giles JA, Hudson EA, Crow J, William D, Walker P. Colposcopic assessment of the accuracy of the cervical cytology screening. *BMJ* 1988; 296:1099-102.
- [16]. Soutter WP, Wisdom S, Brough AK, Monaghan JM. Should patients with mild atypia in cervical smear be referred for colposcopy? *Br J Obstet Gynecol* 1986; 93:70-4.
- [17]. Duncan ID. Guideline for clinical practice and program management. Oxford: National Coordinating Network, NHS cervical screening programme, 1993.
- [18]. WHO .Management of sexually transmitted diseases at district and PHC level 1999; Regional publication SERO; p.25.
- [19]. (Kurman RJ, Malkasian GD Jr, Sedlis A, Solomon D. From Papanicolaou to Bethesda: The rationale for a new cervical cytologic classification. *Obstet Gynecol* 1991; 77: 779-82.)
- [20]. Guldeniz Aksan-Desteli, Turkan Gursu , Cem Murat Baykal, Is the Loop Electrosurgical Excision Procedure Necessary for Minor Cervical Cytological Abnormalities?,*Asian Pacific Journal of Cancer Prevention*,2014,15,305-308.
- [21]. Marchand L, Van Dinter M, Mundt M, Dingel W, Klein G Current cervical cancer screening practices of Dane county, Wisconsin Primary care clinicians. *WMJ* 2003; 102:3540.