



International Journal of Research in Pharmacology & Pharmacotherapeutics



ISSN Print: 2278-2648

IJRPP |Vol.6 | Issue 4 | Oct - Dec - 2017

ISSN Online: 2278-2656

Journal Home page: www.ijrpp.com

Research article

Open Access

Histopathological and x-ray based evaluation of anti-rheumatoid effect of chrysin in freund's induced arthritis in wistar albino rats

Vishnu R¹, Krishnan R²

¹Assistant Professor, Department of Pharmacology, PK Das Institute of Medical Sciences, Vaniamkulam, Kerala.

²Consultant Physiatrist, Indo American Hospital, Brain and Spine Center, Vaikom, Kerala.

*Corresponding author: Dr. Vishnu R

Email: drvishnuradhakrishnan@gmail.com

ABSTRACT

Background

Arthritis is one of the leading cause of disability in the world. A radiographic survey suggested that the prevalence of arthritis rises from 1% below 30 years and 50% in above 60 years. With this background the present study was conducted to evaluate the Anti- rheumatoid effect of chrysin in freund's induced arthritis in rats.

Aim and Objective

To evaluate the anti-rheumatoid effect of Chrysin in freund's induced arthritis in rats.

Materials and Methods

This study was conducted in the Department of Pharmacology, Rajah Muthiah Medical College, Annamalai University. It was done in the period of Jan 2012-Jan 2013 (1 year). 30 rats were divided in two five groups each group of 6 rats. G-I (Distilled water), G-II (Freund's complete adjuvant), G-III (Dexamethasone 0.5 mg/kg), G-IV (Chrysin 50mg/kg) and G-V (Chrysin 100 mg/kg). All the animals were treated with their respective drugs for 56 days. X-ray of rats joint was taken at 1st, 7th, 14th, 28th and 56th day. At the end of experiment Rats were sacrificed and joint was separated and used for histopathology.

Results

G-II rats showed significant changes in joint X-ray and histopathology compared to control group. Co-administration of dexamethasone significantly prevented arthritic changes in joint compared to G-II. High dose chrysin showed effect similar to dexamethasone.

Conclusion

Chrysin administration significantly prevented freund's adjuvant induced arthritis in rats. It can be used in the treatment of rheumatoid arthritis and other inflammatory joint disorders.

Keywords: Arthritis, Inflammation, Freund's complete adjuvant, Chrysin, X-ray, Joint

INTRODUCTION

Arthritis is an inflammatory disorder which affects the joints. The major pathophysiology is development of auto antibodies against the joint proteins. [1-3] As disease progress it affects the organs, blood vessels, skin, muscle and joints.^[4] The antibody and antigen reactions in the joint stimulate the immune Cells leading to damage of the joints. The main symptoms are pain, redness, swelling and rigidity in the joint. [5-7] Arthritis causes impairment of physical activities and movements of the joints. Based on the Pathophysiology it can be classified into two types. One that is due to inflammation is called inflammatory arthritis. Another type there is no inflammation and it is called non-inflammatory arthritis. The osteoarthritis is an example for the non-inflammatory type of arthritis. Arthritis can develop in old age mainly. [8] The studies showed that 1% below 30 years and 50% in people age with 60 years is the prevalence of arthritis. In India 1.5 crore people are affected with arthritis. [9-11] Recent years the prevalence arthritis increased worldwide. It affects females more than males. Arthritis can be treated with Anti-inflammatory drugs and immunosuppressants. Treatments with synthetic drugs produce severe adverse effects. [12] With this background present study was planned and conducted to evaluate the Anti-rheumatoid effect of Chrysin in Freund's complete adjuvant induced rat model.

MATERIALS AND METHODS

Animals

Wistar Albino rats weighing 150-200 grams were obtained from Central Animal House. They were fed on standard rat pellet diet and water was provided in feeding bottle. All the animals were maintained under standard laboratory conditions Temp of 24 °C and humidity of 60-70 %. The study was approved by Institutional Animal Ethics Committee. [13]

Study settings

This study was conducted in the Department of Pharmacology and Central Animal House in Rajah Muthiah Medical College, Annamalai University. The study was done for one year (From Jan 2012 to Jan 2013). The study was approved by Institutional

Research Committee and Institutional Animal Ethics Committee.

Study groups

30 Wistar Albino rats were obtained from Central Animal House. They were divided into 5 groups of each of 6 rats. Group-I (Distilled water), Group-II (Freund's complete adjuvant), Group-III (Dexamethasone 0.5 mg/kg), Group-IV (Chrysin 50 mg/kg) and Group-V (Chrysin 100 mg/kg).

Procedure

Arthritis was induced by inj. of 0.1 ml of 0.5% Freund's complete adjuvant into the tibio tarsal joint of the left hind paw. After injection G-I was treated with distilled water, G-III with dexamethasone and G-IV and V with Chrysin for 56 days. The x-ray of joint was taken on 1st, 7th, 14th, 28th and 56th day. All the rats were sacrificed on 56th day. Joint was dissected out and stored in 10% formalin. The stored specimens were used for histopathology. Slides were stained with H&E stain by standard method. [14]

Statistical analysis

The data was analyzed by Statistical Package for Social Sciences (Version 16.0). One ANOVA (Post hoc) followed by Dunnett t test applied to find the statistical significant between the groups. P value less than 0.05 ($p < 0.05$) considered statistically significant at 95% confidence interval. The data was expressed in mean and standard deviation.

RESULTS

Group-II rats showed significant inflammatory changes in joint x-ray compared to G-I. Group-III showed significant reduction in changes in joints compared to G-II. Group-V showed less pathological changes in joint compared to G-I. The similar results were observed on 1st, 7th, 14th, 28th and 56th day (Image-1,2,3,4,5). G-II joint histology showed dense neutrophilic Infiltration, dense fibrocollagenous tissue and synovial hyperplasia. G-I showed normal histopathology. G-III and V showed significant reduction in histopathological changes in joint compared to G-II. G-IV showed lesser effect compared to G-V (Figure-1,2,3,4,5).

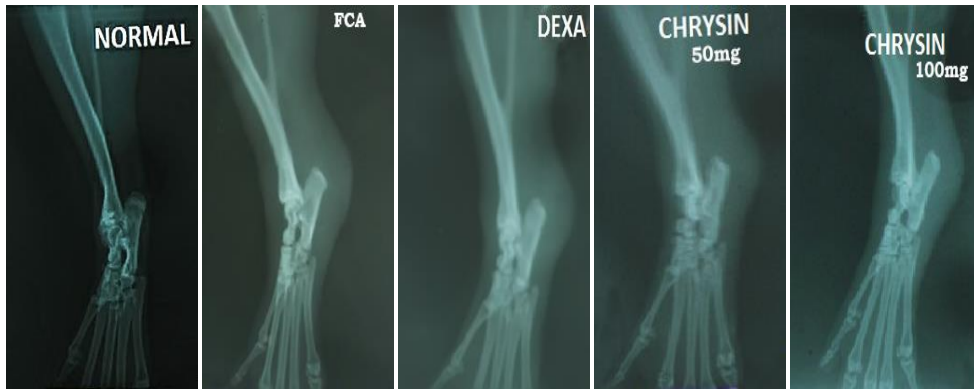


Image-1: X-ray of joints of all the groups on 1st day

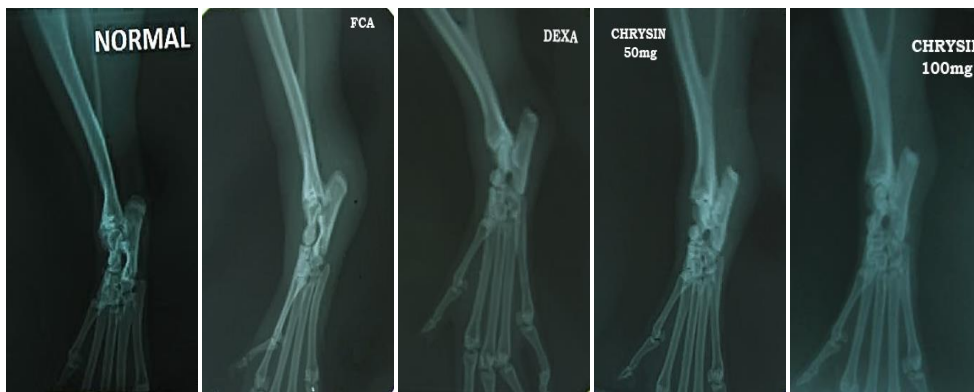

Image-2: X-ray of joints of all the groups on 7th day

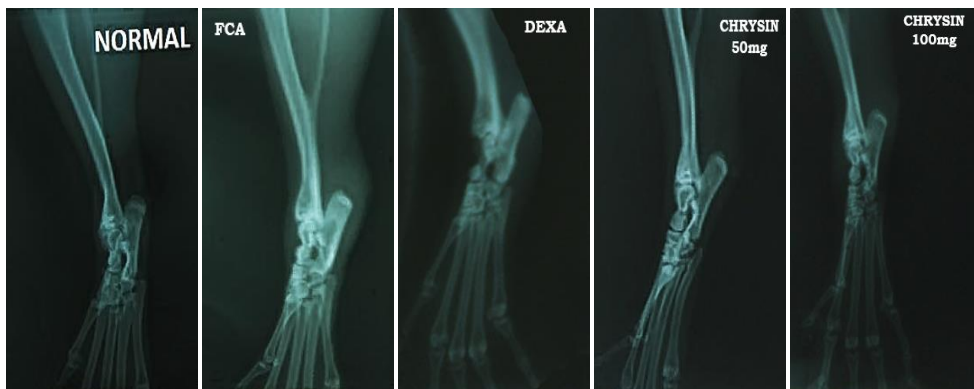


Image-3: X-ray of joints of all the groups on 14th day

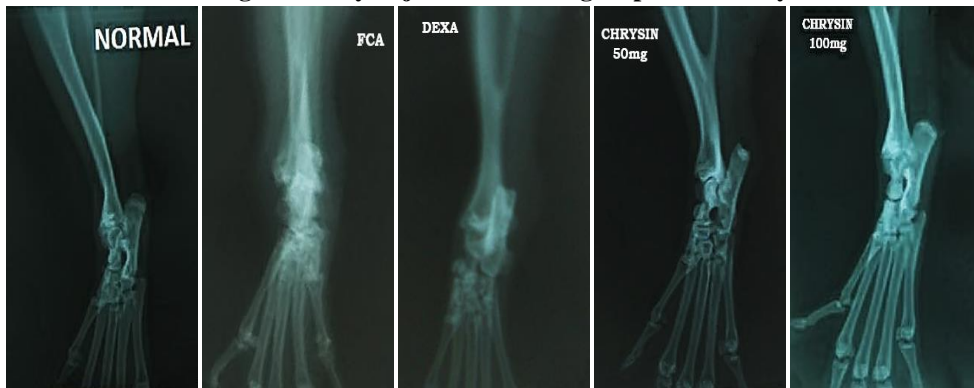

Image-4: X-ray of joints of all the groups on 28th day

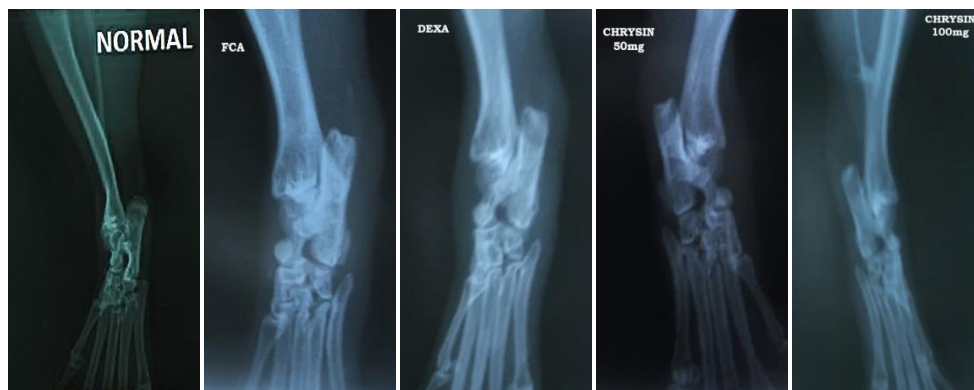

Image-5: X-ray of joints of all the groups on 56th day

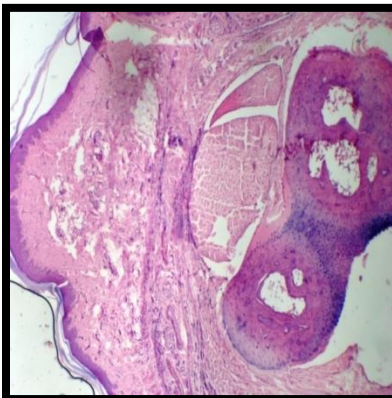

Figure-1: Histology of joint Group-I (Distilled water)

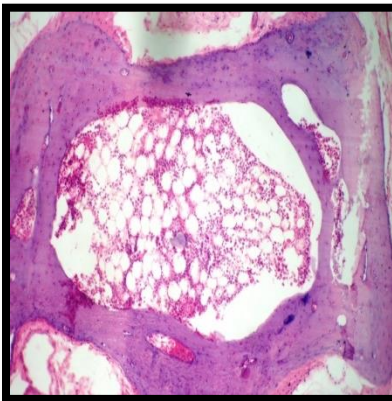


Figure-2: Histology of joint Group-II (Freund's complete adjuvant)

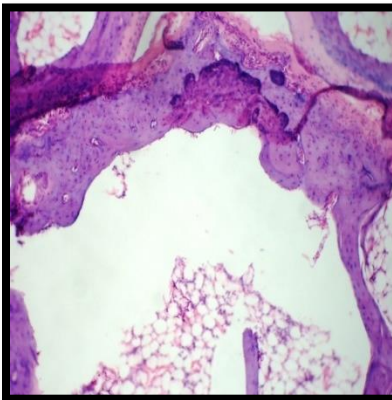


Figure-3: Histology of joint Group-III (Dexamethasone 0.5 mg/kg)

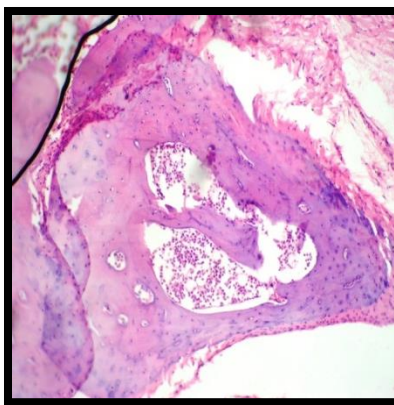


Figure-4: Histology of joint Group-IV (Chrysin 50 mg/kg)

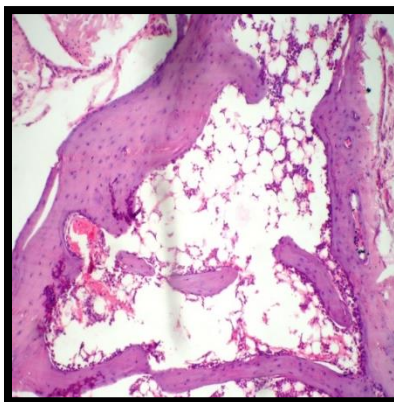


Figure-5: Histology of joint Group-V (Chrysin 100 mg/kg)

DISCUSSION

The arthritis inducing agent Chrysin also known as “Blue passion flower”. These are dihydroxy flavones. Chrysin showed anti-tumor, anti-diabetic, anti-oxidant and anti-inflammatory properties in various animal models. [15-17]. In this study Freund’s complete adjuvant used for the induction of arthritis in rats. Dexamethasone was used as a standard drug. Two graded doses of Chrysin used as test drugs. Dexamethasone Is a known steroid and is used in the treatment of various immune and inflammatory conditions. In this study Chrysin effect was Compared to dexamethasone.

In radiological examination in group-II showed massive soft tissue edema around the joint area. While a marked reduction in soft tissue swelling around the joint was observed in group-IV (Chrysin 50 mg) and group-V (Chrysin 100 mg) and comparable to the standard drug Dexamethasone 0.5 mg (Group-III). In the tibiotarsal joint of normal rats (Group-I), there was presence of normal connective tissue structure with the absence of necrosis. It did

not show any evidence of neutrophilic infiltration. Mamatha K et.al study also showed similar effects of Chrysin in Freund’s induced arthritis in rats. [18]

The histopathological analysis of infected joints showed thickening of synovium, because of increase in number and size of cells in synovial membrane with colonization of neutrophils and plasma cells. Histopathological evaluation of the tibiotarsal joint of control rats (Group-II) showed massive influx of inflammatory cells, synovial hyperplasia with mono and polymorphonuclear cells accumulation in the joint and edema associated with granuloma formation. It also showed the presence of higher degree of necrosis. Treatment with dexamethasone 0.5 mg/kg (Group-III) showed normal connective tissue of tibiotarsal joint with the presence of lower degree of edema. There was absence of necrosis and only minimal neutrophilic infiltration was observed.

Tibiotarsal joint of rats treated with Chrysin 50 mg/kg (Group-IV) showed presence of mild necrosis with low amount of neutrophilic infiltration. It did not show any sign of granuloma formation but mild

edema was present. Necrosis was not observed in this group. Tibiotarsal joint of rats treated with Chrysin 100 mg/kg (Group-V) showed mild skin thickening, presence of almost normal connective tissue structure, fibrocollagenous tissue and synovium with almost minimal neutrophilic infiltrates, with absence of necrosis. Histopathological analysis of Chrysin 50 mg/kg (Group-IV) and Chrysin 100 mg/kg (Group-V) were in fact comparable to that of standard drug Dexamethasone 0.5mg/kg (Group-III). Based on the x-ray and histopathological results of present study proved anti-rheumatoid effect of Chrysin in Freund's

complete adjuvant induced arthritis in Wistar Albino rats.

CONCLUSION

Chrysin showed similar effects like dexamethasone in this study. Administration of Chrysin prevented arthritic changes in joint. From the observations of this study it can be concluded that Chrysin can be given Alone or along with other drugs in the treatment of rheumatoid arthritis. More pre-clinical and clinical trials are further required to explore its mechanism of action and adverse effects.

Conflict of interest: Nil

REFERENCES

- [1]. Arya RK, Jain V. Osteoarthritis of the Knee Joint - An Overview. Journal of Indian Academy of Clinical Medicine 14(2), 2013, 154-62.
- [2]. Parasannasrinivas D, Karthikeya P, Mahima V, Guledgud, Reema SD. Diagnostic imaging in TMJ osteoarthritis: A case report and overview. IJDSR 3(3), 2015, 56-9.
- [3]. Delisa AJ, Walter RF, Bruce MG, Nicolas EW, Lawrence RR. Rehabilitation of the patient with rheumatic diseases. Lippincott Williams & Wilkins, 40, 2010, 1015-21.
- [4]. Van der heide A, Jacobs JW. The effectiveness of early treatment with second line anti - rheumatic drugs . Annals of Internal Medicine 124, 1996, 699-707.
- [5]. Emery P, Foster W and Suarez M. Rheumatoid arthritis. Clinical Evidence 5, 2002, 1107-21.
- [6]. Kitas GD, Erb N, Tackling Ischemic Heart Disease in Rheumatoid Arthritis. Rheumatology 42, 2003, 607-13.
- [7]. Goronzy JJ, Weyand CM. Rheumatoid arthritis: Epidemiology, Pathology and pathogenesis. primer on the rheumatic diseases. Arthritis Foundation 2, 1997, 155-162.
- [8]. Panoulas VF, Metsios GS, Pace AV, John H. Hypertension in Rheumatoid Arthritis. Rheumatology 47, 2008, 1286-98.
- [9]. Genovese MC. Abatacept for Rheumatoid Arthritis Refractory to TNF- α inhibition. New England Journal of Medicine 353, 2005, 1114-6.
- [10]. Brandt Kenneth D, Dieppe P Radin Eric. Etiopathogenesis of osteoarthritis. Medical Clinics of North America 93(1), 2009, 1-24.
- [11]. Delisa AJ, Walter RF, Bruce MG, Nicolas EW, Lawrence RR. Rehabilitation of the patient with Rheumatic diseases. Lippincott Williams & Wilkins, 40, 2010, 1015-21.
- [12]. Ashman RB, Papadimitriou JM. Production and function of cytokines. IIR 18(1), 1995, 23-30.
- [13]. Ajay DK, Prashant VP, Uday NH, Rabindra KN, Haidarali MS. Anti-inflammatory and artharthritic activity of anthraquinone derivatives in rodents. IJI 2(1), 2014, 1-12.
- [14]. Snehalatha U, Anburajan M, Venkatraman B, Menaka M. Evalaution of complete freund's adjuvant induced arthritis in a Wistar rat model. Comparison of thermography and histopathology. J Rheumatol 72(4), 2013, 375-82.
- [15]. Boon YK, Siang Lc, Prabha B. Apoptotic effects of chrysin in Human Cancer Cell Lines. IJMS 11, 2010, 2188-99.
- [16]. Lukacinova A, Moizis J, Benacka R, Keller J, Maguth T, Kurila P. Preventive effects of flavonoids on Alloxan-induced Diabetes Mellitus in Rats . ACTAVET BRNO 77, 2008, 175 -182.
- [17]. Teng GG, Turkiewicz AM, Moreland LW: Abatacept : A costimulatory inhibitor for treatment of rheumatoid arthritis. Expert opinion inbiologicals therapy 5, 2005, 1245.
- [18]. Mamatha K, Rodda HC, Ciddi V, Bookya K. Anti-arthritis activity of root bark of *Oroxylum indicum (L.)* vent against adjuvant-induced arthritis. Pharmacognosy Res 5(2), 2013, 121-.